

# Treatment of Chronic Elbow Tendinosis With Buffered Platelet-Rich Plasma

Allan Mishra,\* MD, and Terri Pavelko, PAC, PT

*From the Department of Orthopedic Surgery, Menlo Medical Clinic, Stanford University Medical Center, Menlo Park, California*

**Background:** Elbow epicondylar tendinosis is a common problem that usually resolves with nonoperative treatments. When these measures fail, however, patients are interested in an alternative to surgical intervention.

**Hypothesis:** Treatment of chronic severe elbow tendinosis with buffered platelet-rich plasma will reduce pain and increase function in patients considering surgery for their problem.

**Study Design:** Cohort study; Level of evidence, 2.

**Methods:** One hundred forty patients with elbow epicondylar pain were evaluated in this study. All these patients were initially given a standardized physical therapy protocol and a variety of other nonoperative treatments. Twenty of these patients had significant persistent pain for a mean of 15 months (mean, 82 of 100; range, 60-100 of 100 on a visual analog pain scale), despite these interventions. All patients were considering surgery. This cohort of patients who had failed nonoperative treatment was then given either a single percutaneous injection of platelet-rich plasma (active group,  $n = 15$ ) or bupivacaine (control group,  $n = 5$ ).

**Results:** Eight weeks after the treatment, the platelet-rich plasma patients noted 60% improvement in their visual analog pain scores versus 16% improvement in control patients ( $P = .001$ ). Sixty percent (3 of 5) of the control subjects withdrew or sought other treatments after the 8-week period, preventing further direct analysis. Therefore, only the patients treated with platelet-rich plasma were available for continued evaluation. At 6 months, the patients treated with platelet-rich plasma noted 81% improvement in their visual analog pain scores ( $P = .0001$ ). At final follow-up (mean, 25.6 months; range, 12-38 months), the platelet-rich plasma patients reported 93% reduction in pain compared with before the treatment ( $P < .0001$ ).

**Conclusion:** Treatment of patients with chronic elbow tendinosis with buffered platelet-rich plasma reduced pain significantly in this pilot investigation. Further evaluation of this novel treatment is warranted. Finally, platelet-rich plasma should be considered before surgical intervention.

**Keywords:** platelet-rich plasma (PRP); tennis elbow; lateral epicondylitis; tendonitis; tendinosis

Elbow epicondylar tendinosis is a common problem for patients whose activities require strong gripping or repetitive wrist movements. Histologic specimens from chronic cases confirm that tendinosis is not an acute inflammatory condition but rather a failure of the normal tendon repair mechanism associated with angiofibroblastic degeneration.<sup>8</sup> The cause of elbow tendinosis is most likely a combination of mechanical overloading<sup>21</sup> and abnormal microvascular

responses.<sup>19</sup> Further research into the precise cause of tendinosis is, however, still needed.

Numerous methods have been advocated for treating elbow tendinosis, including rest, nonsteroidal anti-inflammatory medication, bracing, physical therapy, iontophoresis,<sup>15</sup> extracorporeal shock wave therapy, and botulism toxin.<sup>9</sup> Injections of corticosteroids or whole blood,<sup>3</sup> and various types of surgical procedures have also been recommended. The utility of several of these treatments has recently come into question. For example, one recent report noted that there is no difference between using corticosteroid or local anesthetic when treating elbow tendinosis with an injection.<sup>1</sup>

In this study, we evaluated the use of platelet-rich plasma (PRP) as a treatment for chronic severe epicondylar tendinosis. Platelet-rich plasma contains a more concentrated amount of platelets than does whole blood. Within platelets are powerful growth factors, including platelet-derived growth factor, transforming growth factor beta, and epidermal growth factor. Slater et al<sup>17</sup> reported that the addition of platelets to a culture medium stimulated the proliferation

\*Address correspondence to Allan Mishra, MD, Menlo Medical Clinic, Stanford University Medical Center, Department of Orthopedic Surgery, 1300 Crane Street, Menlo Park, CA 94025 (e-mail: allan\_mishra@yahoo.com).

One or more of the authors have declared a potential conflict of interest. Part of this research was funded by Cell Factor Technologies, and Dr Allan Mishra is a consultant for this company. He has also received reimbursement for attending a symposium.

of human osteoblast-like cells. They further proposed that exogenous platelet growth factors may play a significant role in fracture repair.<sup>17</sup>

A recent review of common growth factors suggested PRP may be useful for tendon and ligament healing in vivo.<sup>11</sup> The specific goal of this investigation was to measure the efficacy of buffered PRP as a potential new treatment for chronic severe elbow tendinosis.

## MATERIALS AND METHODS

The study design and protocol were evaluated and approved by the authors' investigational review board. This board refused to allow the drawing and discarding of 55 mL blood that would be required to blind the patients to their treatment. All patients signed a detailed informed consent form. Before starting the formal study, 2 healthy volunteers were treated with the PRP formulation and the protocol. No adverse effects were noted in these patients at 1 month, 3 months, 6 months, or 1 year after the procedure.

### Patient Data

One hundred forty patients were evaluated in this study. Criteria for participation included elbow epicondylar pain for longer than 3 months of at least 60 of 100 on a visual analog score (0, no pain; 100, maximum pain possible), in spite of completing a standardized stretching and strengthening protocol. All patients had the same physical therapist instruct them in the same set of exercises. This specific protocol was posted on a Web site ([www.emedx.com](http://www.emedx.com)) for patients to follow. Patients also had failure with some combination of nonsteroidal medication, bracing, or corticosteroid injections. Elbow epicondylar tendinosis was defined as pain over the lateral or medial epicondyle, with direct palpation and pain at the elbow with resisted wrist extension (for lateral tendinosis) and resisted wrist flexion (for medial tendinosis). Exclusion criteria included pregnancy, history of carpal tunnel syndrome, cervical radiculopathy, and systemic disorders such as diabetes, rheumatoid arthritis, and hepatitis. Twenty (15%) of the 140 patients evaluated met these strict inclusion-exclusion criteria and were enrolled in the study.

There was a total of 15 PRP-treated and 5 control patients included in this study. The PRP-treated patients (15 patients: 14 lateral tendinosis, 1 medial tendinosis) received an injection of PRP that had been buffered to physiologic pH. The duration of symptoms in this group was 15.3 months, and the mean patient age was 48.1 years. The control patients (5 patients: 5 lateral tendinosis) received an injection of bupivacaine with epinephrine. The mean duration of symptoms in this group was 11.8 months, and the mean age was 42.2 years. Ten of the patients included in this report were part of a consecutive series, and 10 were part of a randomized trial. The randomization of the second group was done with an envelope randomization protocol. Both groups of patients were told that needling of the tendon by itself may produce improvement in symptoms. All patients were evaluated and treated during the same time frame (2002-2004).

### Platelet-Rich Plasma Preparation

Fifty-five milliliters whole blood was collected from the uninvolved arm into a 60-mL syringe that contained 5 mL sodium citrate. A peripheral complete blood count was also collected at the time of the initial blood draw. The blood was then prepared according to the GPS System instructions (Cell Factor Technologies, Warsaw, Ind). This device is a desktop-size centrifuge with disposable cylinders for the blood. All the procedures were performed in the same office setting. Approximately 5 mL PRP was obtained for each patient. The PRP was then buffered to physiologic pH using 8.4% sodium bicarbonate. No activating agent was used. Two milliliters of this PRP was then sent to the laboratory for analysis of platelet concentration, whereas the remaining 2 to 3 mL was used to inject into the patient. On average, 3.31 million platelets were given to each PRP-treated patient via this injection. The total number of platelets per milliliter in the PRP represented a mean increase of 539% compared with whole blood values in the active patient group. The total time from blood draw to injection in the patients was about 30 minutes. No specialized equipment, other than the GPS machine, was required. The cost of the machine and the kit with all the materials to perform the procedure has not been determined because they are not yet commercially available.

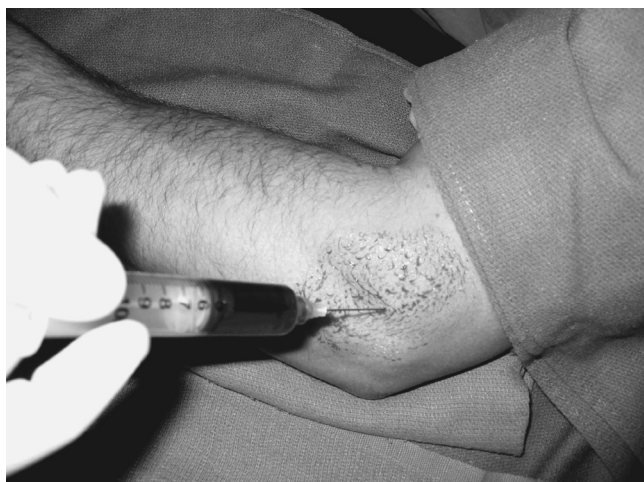### Injection Technique

Initially, bupivacaine with epinephrine was infiltrated into the skin and subcutaneous tissue of both groups as a local field block. Approximately 0.5 mL was also injected directly into the area of maximum tenderness. Then, either 2 to 3 mL PRP or 2 to 3 mL bupivacaine with epinephrine was injected using a 22-g needle into the common extensor or flexor tendon using a peppering technique. This technique involved a single skin portal and then 5 penetrations of the tendon (Figure 1).

### Postprocedure Protocol

Immediately after the injection, the patient was kept in a supine position without moving the arm for 15 minutes. Patients were sent home with instructions to limit their use of the arm for approximately 24 hours and use hydrocodone or acetaminophen for pain. The use of nonsteroidal medication was prohibited. After 24 hours, patients were given a standardized stretching protocol to follow for 2 weeks. A formal strengthening program was initiated after this stretching. At 4 weeks after the procedure, patients were allowed to proceed with normal sporting or recreational activities as tolerated.

A 100-mm visual analog pain score (0, no pain; 100, worst pain possible) and a modified Mayo elbow score (best score, 100) were used as outcome measures. The patients were examined at 4 weeks, 8 weeks, and 6 months after the index procedure. A final follow-up overall evaluation was also done. Paired and unpaired *t* tests were used to statistically compare the 2 groups of patients. Initially, the visual analog pain



**Figure 1.** Platelet-rich plasma injection technique.

scores and modified Mayo elbow scores were not statistically different between the 2 groups. All patients were either fair or poor as measured by the Mayo elbow score (Table 1).

## RESULTS

During follow-up examinations, all patients reported complete compliance with the recommended postprocedure exercise program. All patients had the same physical therapist instruct them in this standardized protocol. No complications were noted in either group at any time. Specifically, there were no infections, neurovascular changes, or worsening of the patients' epicondylar pain. Initially, the PRP-treated patients had a mean visual analog pain score of 80.3 (range, 60-100) and a mean Mayo elbow score of 50.3 (range, 38-68). The control patients had a mean visual analog pain score of 86 (range, 80-100) and a mean Mayo elbow score of 50 (range, 43-53).

Four weeks after the procedure, PRP-treated patients reported a mean of 46% improvement (80.3 to 43.4) in their visual analog pain scores versus 17% improvement (86.0 to 71.0) in the control patients ( $P = .028$ ) (Figure 2). Also, after 4 weeks, Mayo elbow scores had improved 42% (50.3 to 71.3) in PRP-treated patients versus a 20% improvement (49.5 to 59.5) in control patients ( $P = .120$ ) (Figure 3).

Eight weeks after the treatment, PRP-treated patients reported a mean of 60% improvement (80.3 to 32.0) in their visual analog pain scores versus a 16% improvement (86 to 72) in control patients ( $P = .001$ ) (Figure 2). Platelet-rich plasma patients also had a 52% improvement (50.3 to 76.3) in their Mayo elbow scores versus 14% improvement (49.5 to 56.5) in control patients ( $P = .008$ ) at this time frame (Figure 3).

After 8 weeks, 60% (3 of 5) of the control patients had either sought treatment outside of the protocol or had formally withdrawn from the study. This factor limited further data evaluation to only the PRP-treated patients. At 6 months, the PRP-treated patients' visual analog pain scores had improved a mean of 81% over baseline ( $P = .0001$ ) (Figure 4), and their Mayo elbow scores had improved 72% ( $P = .0001$ ) (Figure 5).

**TABLE 1**  
Modified Mayo Clinic Performance Index for the Elbow

Mayo Index	Points
Parameter/findings	
Pain	
None	45
Minimal	37.5
Mild	30
Moderate	15
Severe	0
Motion	
Full motion	20
Stability	
No clinical laxity	10
Daily Function/Performance	
Combing hair	
Able	5
Able with pain	2.5
Unable	0
Eating	
Able	5
Able with pain	2.5
Unable	0
Hygiene	
Able	5
Able with pain	2.5
Unable	0
Dressing	
Clothing	
Able	5
Able with pain	2.5
Unable	0
Shoes and socks	
Able	5
Able with pain	2.5
Unable	0
Interpretation	
Excellent	>90
Good	75-89
Fair	60-74
Poor	<60

The 2 remaining control patients were also interviewed; one had a pain score of 0 of 100, and one had a pain score of 50 of 100. Their Mayo elbow scores were 100 and 70, respectively.

At final follow-up (mean, 25.6 months; range, 12-38 months), the PRP-treated patients reported a 93% reduction (mean, 5.7 of 100; range, 0-40) in pain when compared with before the treatment ( $P < .001$ ). Ninety-three percent of these patients were completely satisfied with the treatment, and 7% were partially satisfied. This same 93% were essentially pain free (10 or less of 100 on visual analog scale). One patient reported 40 of 100 on the scale at final follow-up but was still partially satisfied with her treatment. Overall, the patients reported engaging in a mean of 99% (range, 90%-100%) of the activities of daily living and 94% (range, 75%-100%) of their work or sporting activities.

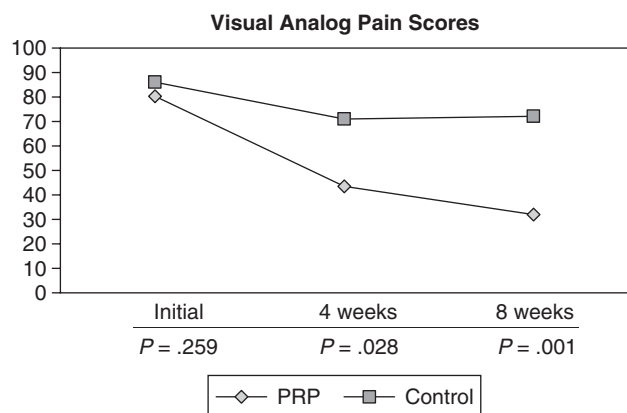


Figure 2. Visual analog pain scores for the group treated with platelet-rich plasma (PRP) and the control group.

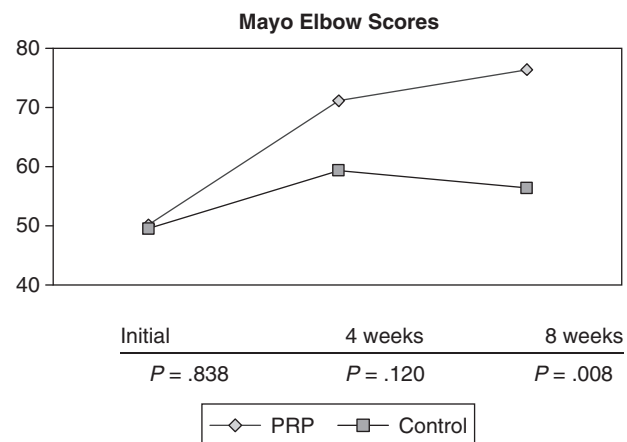


Figure 3. Mayo elbow scores for the group treated with platelet-rich plasma (PRP) and the control group.

DISCUSSION

Elbow epicondylar tendinosis is a common problem with many possible treatments. Quick cessation of symptoms is important to patients and is economically advantageous. If neither rest nor simple treatment provides a satisfactory remedy, a patient may pursue several other options. The most commonly recommended treatment is physical therapy. A recent meta-analysis of physical therapy, however, noted that there is insufficient evidence to conclude that it has any lasting value.<sup>18</sup> We also surveyed owners of 8 physical therapy clinics within 15 miles of our office to determine the mean cost of treatment per patient per episode of elbow tendinosis. The typical treatment period consisted of an initial evaluation and 10 follow-up visits. The mean estimated cost was \$1200. Corticosteroid injections have also been used extensively for this problem, but studies show that there is conflicting evidence about their efficacy.<sup>1,14</sup> Jobe and Ciccotti<sup>8</sup> also concluded that superficial injection of corticosteroid may result in subcutaneous atrophy and that intra-tendinous injection may lead to permanent adverse changes within the ultrastructure of the tendon. Despite these

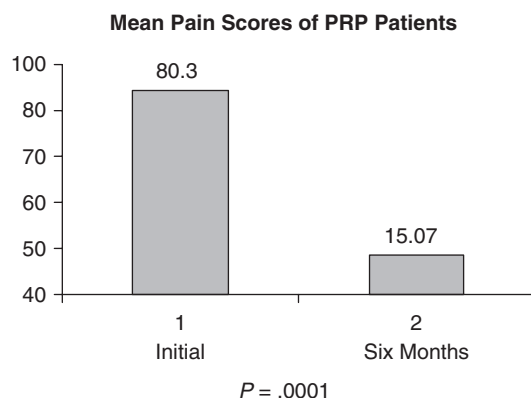


Figure 4. Mean pain scores of patients treated with platelet-rich plasma (PRP).

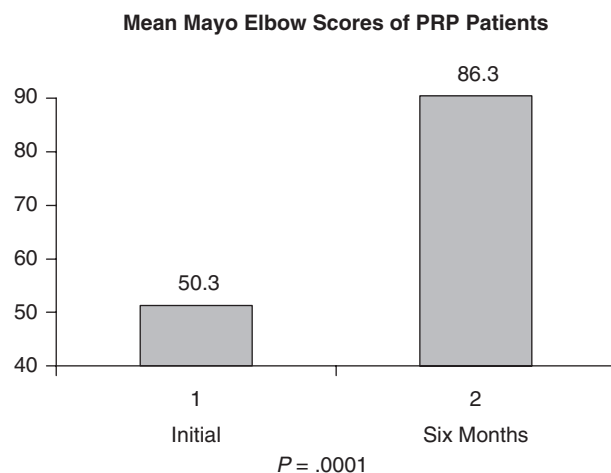


Figure 5. Mean Mayo elbow scores for patients treated with platelet-rich plasma (PRP).

issues, corticosteroid is still widely used. Hill et al<sup>6</sup> surveyed 400 members of the American Academy of Orthopaedic Surgeons and found that 93% had given a corticosteroid injection for elbow epicondylitis. Extracorporeal shock wave therapy also has recently gained popularity. A recent randomized double-blind study, however, showed that this treatment is no better than placebo.<sup>13</sup>

Biologic treatments in orthopaedics are just beginning to evolve. Bone morphogenic proteins and other growth factors have been extensively studied in vitro. These important cytokines are now being tested in vivo.<sup>4</sup> Marx et al<sup>12</sup> confirmed the value of adding PRP to bone graft in maxillofacial surgery. They showed that PRP-enhanced autografts were 50% more dense than were autografts alone at 6 months in a mandibular defect model.<sup>12</sup> Data were recently presented that noted PRP-enhanced allograft had significantly increased shear strength and energy absorption when compared to allograft alone.<sup>7</sup> Platelet-rich plasma may also be helpful for wound healing.<sup>5</sup> An animal study, however, found that PRP does not enhance demineralized bone matrix's osteoinductive capacity and may actually inhibit it.<sup>16</sup> Platelet-rich plasma injections have also been used to

treat recalcitrant plantar fasciitis. Barrett and Erredge<sup>2</sup> reported a 78% success rate with 1-year follow-up. This same study also documented a decrease in plantar fascia thickness over time when treated with PRP.<sup>2</sup> Edwards and Calandrumlio,<sup>3</sup> using whole blood, noted a 79% success rate when treating lateral epicondylitis. The follow-up time, however, was short (9.5 months), and 32% of the time, multiple injections were required.

We postulate that the concentrated growth factors within PRP work in concert to initiate a healing response within a damaged tendon. This hypothesis is supported by in vitro data from Klein et al.<sup>10</sup> They reported that transforming growth factor beta significantly increases type I collagen production in tendon sheath fibroblasts. This same mechanism may be at work in our in vivo model of chronic severe elbow tendinosis. It may also be possible that PRP helps recruit bone marrow-derived stem cells to the site of injection or somehow moderates the microvascular environment. Further study into the mechanisms by which PRP works is needed. We chose to study elbow tendinosis because it is clinically very common and does not involve a weightbearing limb. We have, however, also treated several cases of plantar fasciitis and quadriceps and patellar tendinosis with these methods with good results.

The patients in this study were vigorously screened before enrollment. We evaluated 140 patients for this study and enrolled only 15%. This left the study with the most severe tendinosis patients and eliminated any patient who had improved with time or nonoperative treatment. In the present investigation, the patients treated with buffered PRP did significantly better than control patients did at 4 weeks and 8 weeks. After 8 weeks, 60% of the control patients either formally withdrew from the study or sought treatment outside of the protocol. This factor, unfortunately, limited further direct comparison. We were unable to blind the patients because our institutional review board refused to allow the drawing and discarding of a small amount of blood that would be required to fully blind the patients. This factor may have influenced the control group and may explain why this group did not respond to the needling technique. At 6 months after treatment, however, the PRP-treated patients improved a mean of 81% in their visual analog pain scores and 72% in their Mayo elbow scores. Two years after treatment, the PRP-treated patients reported a 93% reduction in pain. This finding is similar to the 95% reduction in pain reported in patients treated with suture anchor repair by Thornton et al.<sup>20</sup> Of importance, no PRP-treated patient was worse after treatment, and there were no complications in this study.

The limitations of this study include lack of a randomized control group and the small number of patients. This study, however, was designed only as a pilot investigation. A double-blind, placebo-controlled, prospective multicenter trial has now been approved, which should help better evaluate PRP as a treatment for elbow tendinosis. Further study of PRP versus whole blood or cortisone should also be performed in the future.

This report outlines the first in vivo human investigation of autologous growth factors as a treatment for chronic severe elbow tendinosis in patients who have failed nonoperative treatment. The data suggest buffered PRP may be an alternative to surgery in patients with this disorder. In the present investigation, the PRP-treated patients

demonstrated significant improvement with a single injection that was sustained over time with no reported complications.

## ACKNOWLEDGMENT

We thank James Cox for his help in the preparation of the PRP and his contributions to this research.

## REFERENCES

1. Altay T, Gunal I, Ozturk H. Local injection treatment for lateral epicondylitis. *Clin Orthop Relat Res.* 2002;398:127-130.
2. Barrett S, Erredge S. Growth factors for chronic plantar fasciitis. *Podiatr Today.* 2004;17:37-42.
3. Edwards S, Calandrumlio J. Autologous blood injections for refractory lateral epicondylitis. *J Hand Surg Am.* 2003;28:272-278.
4. Einhorn T. Clinical applications of recombinant human BMPs: early experience and future development. *J Bone Joint Surg Am.* 2003;85(suppl 3):82-88.
5. Henderson J, Cupp C, Ross E, et al. The effects of autologous platelet gel on wound healing. *Ear Nose Throat J.* 2003;82:598-602.
6. Hill J, Trapp R, Colliver J. Survey on the use of corticosteroid injections by orthopedists. *Contemp Orthop.* 1989;18:39-45.
7. Jensen T, Bechtold J, Chen X, Elmengaard B, Soballe K. Platelet concentrate improves fixation achieved with morselized bone allograft around non-cemented implants. Poster presented at: 49th Annual Meeting of the Orthopedic Research Society; February 2-5, 2003; New Orleans, La. Poster 1377.
8. Jobe F, Ciccotti M. Lateral and medial epicondylitis of the elbow. *J Am Acad Orthop Surg.* 1994;2:1-8.
9. Keizer S, Rutten H, Pilot P, Morre H, Verburg A. Botulinum toxin injection versus surgical treatment for tennis elbow. *Clin Orthop Relat Res.* 2002;401:125-131.
10. Klein M, Yalamanchi N, Pham H, Longaker M, Chang J. Flexor tendon healing in vitro: effects of TGF- $\beta$  on tendon cell collagen production. *J Hand Surg Am.* 2002;27:615-620.
11. Malloy T, Wang Y, Murrell G. The roles of growth factors in tendon and ligament healing. *Sports Med.* 2003;33:381-394.
12. Marx R, Carlson E, Eichstaedt R, Schimmele S, Strauss J, Georgeff K. Platelet-rich plasma: growth factor enhancement for bone grafts. *Oral Surg Oral Med Oral Pathol Oral Radiol Endod.* 1998;85:638-646.
13. Melikyan E, Shahin E, Miles J, Bainbridge L. Extracorporeal shock-wave treatment for tennis elbow: a randomized double-blind study. *J Bone Joint Surg Br.* 2003;85:852-855.
14. Newcomer K, Laskowski E, Idank D, McLean R, Egan K. Corticosteroid injection in early treatment of lateral epicondylitis. *Clin J Sport Med.* 2001;11:214-222.
15. Nirschl R, Rodin D, Ochiai D, Maartmann-Moe C. Iontophoretic administration of dexamethasone sodium phosphate for acute epicondylitis: a randomized, double-blinded, placebo-controlled study. *Am J Sports Med.* 2003;31:189-195.
16. Ranly D, McMillan J, Keller T, et al. Platelet-derived growth factor inhibits demineralized bone matrix-induced intramuscular cartilage and bone formation: a study of immunocompromised mice. *J Bone Joint Surg Am.* 2005;87:2052-2064.
17. Slater M, Patava J, Kingham K, Mason R. Involvement of platelets in stimulating osteogenic activity. *J Orthop Res.* 1995;13:655-663.
18. Smidt N, Assendelft W, Arola H, et al. Effectiveness of physiotherapy for lateral epicondylitis: a systematic review. *Ann Med.* 2003;35:51-62.
19. Smith R, Papadopolous E, Mani R, Cawley M. Abnormal microvascular responses in lateral epicondylitis. *Br J Rheum.* 1994;33:1166-1168.
20. Thornton S, Rogers J, Prickett W, Dunn W, Allen A, Hannafin J. Treatment of recalcitrant lateral epicondylitis with suture anchor repair. *Am J Sports Med.* 2005;33:1558-1564.
21. Wang J, Iosifidis M, Fu F. Biomechanical basis for tendinopathy. *Clin Orthop Relat Res.* 2006;443:320-332.